

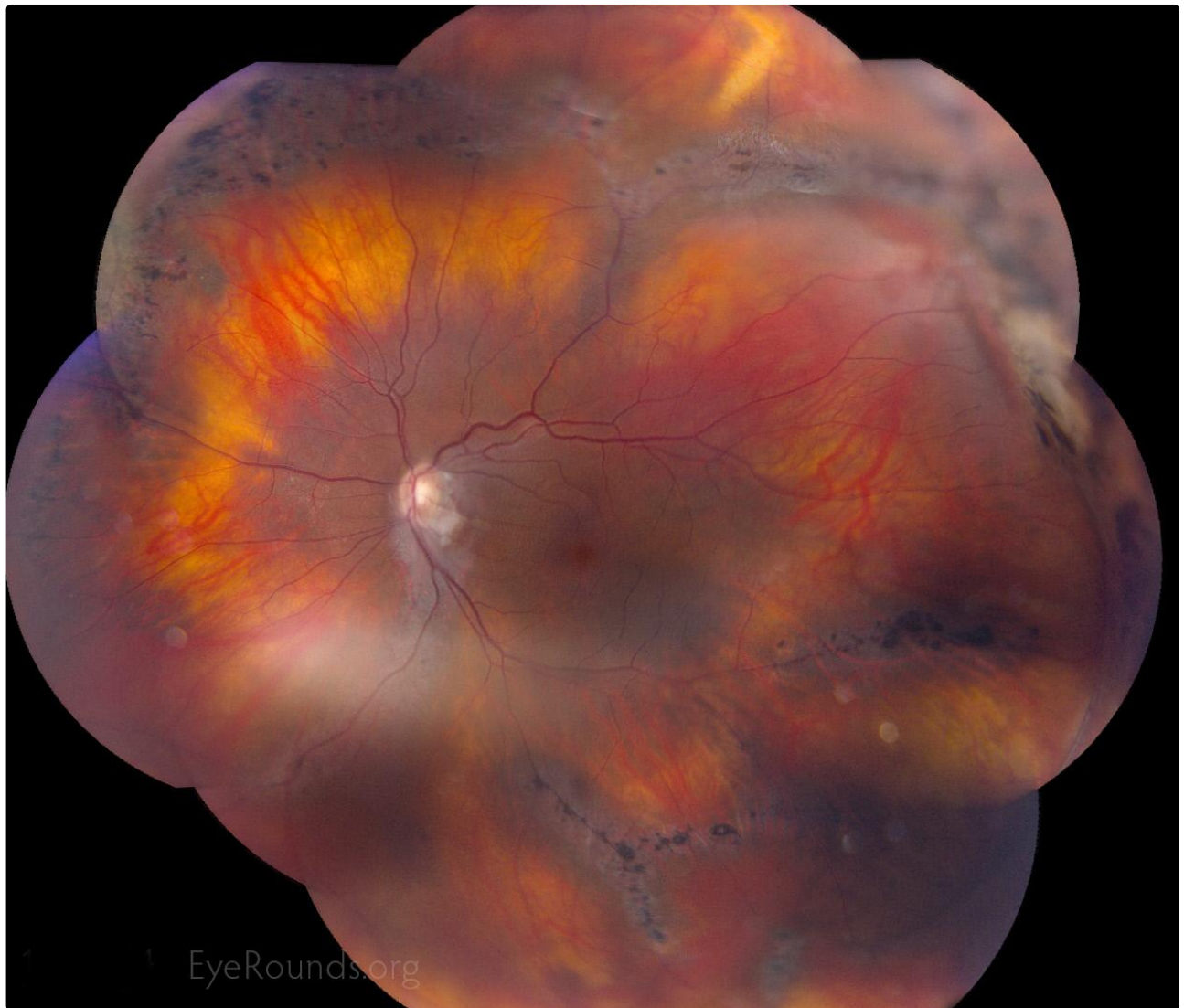
## Radial Lattice Degeneration in Stickler's syndrome

**Category(ies):** Retina, Vitreous

**Contributor:** [David Phillips, MD](#)

**Photographer:** Toni Venckus, CRA

Extensive radial lattice degeneration is noted in this patient with molecularly confirmed Stickler's syndrome (COL2A1 mutation), a condition with autosomal dominant inheritance. The patient has had a retinal detachment in this eye with repair via scleral buckle and cryotherapy, seen on the temporal aspect in this photo.



Caption

 Enlarge

 Download

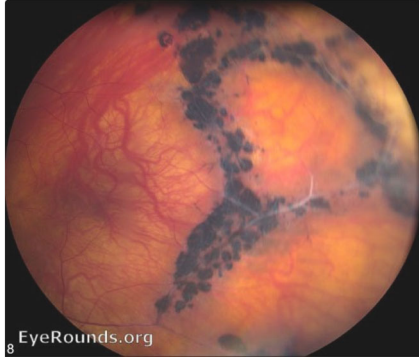
## Image Permissions:



Ophthalmic Atlas Images by [EyeRounds.org](http://EyeRounds.org), [The University of Iowa](http://The University of Iowa) are licensed under a [Creative Commons Attribution-NonCommercial-NoDerivs 3.0 Unported License](https://creativecommons.org/licenses/by-nc-nd/3.0/).



## Related Articles



[Related Atlas Entry: Radial lattice in Stickler's syndrome](#)

## Address

University of Iowa  
Roy J. and Lucille A. Carver College  
of Medicine  
Department of Ophthalmology and  
Visual Sciences  
200 Hawkins Drive  
Iowa City, IA 52242

[Support Us](#)

## Legal

Copyright © 2019 The University of  
Iowa. All Rights Reserved  
[Report an issue with this page](#)  
[Web Privacy Policy](#) |  
[Nondiscrimination Statement](#)

## Related Links

[Cataract Surgery for Greenhorns](#)  
[EyeTransillumination](#)  
[Gonioscopy.org](#)  
[Iowa Glaucoma Curriculum](#)  
[Iowa Wet Lab](#)  
[Patient Information](#)  
[Stone Rounds](#)  
[The Best Hits Bookshelf](#)

## EyeRounds Social Media

Follow



[Receive notification of new cases,  
sign up here](#)  
[Contact Us](#)  
[Submit a Suggestion](#)